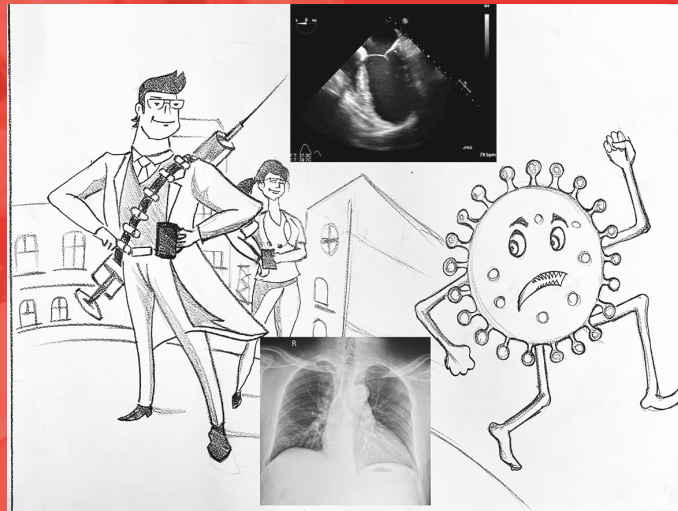




# Annals of Cardiac Anaesthesia

## In this issue:

- The Neurocognitive Outcomes of Hemodilution in Adult Patients Undergoing Coronary Artery Bypass Grafting
- Epidural Analgesia and Abnormal Coagulation in Patients Undergoing Minimal Invasive Repair of Pectus Excavatum
- Intraoperative Evaluation of Renal Resistive Index with TEE
- Long-Term Performance of Untreated Fresh Autologous Pericardium as a Valve Substitute in Pulmonary Position
- Prospective National Audit of Major Gastrointestinal Complications of TEE Studies in Children
- ProtekDuo as Double Lumen Return Cannula in V-VP ECMO Configuration: A First-In-Man Method Description



An Official Publication of  
Indian Association of Cardiovascular  
Thoracic Anaesthesiologists

Online full text at  
[www.annals.in](http://www.annals.in)

# Long-Term Performance of Untreated Fresh Autologous Pericardium as a Valve Substitute in Pulmonary Position

Shantanu Pande, Amitabh Arya<sup>1</sup>, Surendra K. Agarwal, Prabhat Tewari<sup>2</sup>, Aditya Kapoor<sup>3</sup>, Neetu Soni<sup>4</sup>, Sunil Kumar<sup>4</sup>

Departments of Cardiovascular and Thoracic Surgery, <sup>1</sup>Nuclear Medicine, <sup>2</sup>Anaesthesiology, <sup>3</sup>Cardiology and <sup>4</sup>Radiology, Sanjay Gandhi Postgraduate Institute of Medical Sciences, Lucknow, Uttar Pradesh, India

## ABSTRACT

**Background:** Pulmonary regurgitation is imminent after transannular patch (TAP). We analyze the long-term performance of untreated autologous pericardium (UAP) as valve substitute at pulmonary position in patients requiring TAP.

**Material and Methods:** This cross-sectional study include patients operated between 2007 and 2012 (n = 92). A sample of 19 patients was selected for this study which had a follow-up of more than 3 years. This includes patients with no TAP (n = 4) and with TAP and valve substitute, a monocusp (n = 11) or a tricuspid valve (n = 4) at neopulmonary annulus. Patients underwent echocardiography for assessment of right ventricle function and 18 fluoro-deoxyglucose PET CT scan for measurements of valve substitute at neopulmonary annulus. The target to blood ratio (TBR) of uptake of glucose by monocusp was measured at the cooptation edge of the neopulmonary valve.

**Results:** The median age of the patients is 14 (9 – 37). RV function is preserved (TAPSE 18.9 (10.6 – 22.8)) at a mean follow-up of 4 years (3-9). The measurements of monocusp shows a shrinkage in height of the cusp by 35.5% (70% – 1.0%) and length by 7% (-44% - +104%). There was less shrinkage observed in patients below 15 years of age. The TBR of monocusp was 0.945 (0.17 – 3.35) with a strong correlation between the TBR values of aortic valve leaflet and monocusp leaflet of same patient.

**Conclusion:** The UAP is functional and successful as a valve substitute at neo pulmonary annulus at long-term follow-up. It has resisted calcification and has shown uptake of glucose in physiological limits.

**Keywords:** Heart valve, pulmonary valve, pulmonary stenosis

**Address for correspondence:** Dr. Shantanu Pande, Department of Cardiovascular and Thoracic Surgery, Sanjay Gandhi Postgraduate Institute of Medical Sciences, Lucknow - 226 014, Uttar Pradesh, India.

E-mail: shantanupande@hotmail.com

**Submitted:** 21-Feb-2021 **Revised:** 20-May-2021 **Accepted:** 05-Jun-2021 **Published:** 11-Apr-2022

## BACKGROUND

Pulmonary regurgitation (PR) is an integral downside of intracardiac repair in tetralogy of Fallot (TOF) requiring a transannular patch.<sup>[1]</sup> Free PR that arises due to transannular patch for reconstruction of right ventricular outflow tract has detrimental perioperative and long-term results. During early postoperative period, severe PR causes low cardiac output.<sup>[2]</sup> While, if PR persists for long-term it can cause

right ventricle dysfunction and subsequently pulmonary valve replacement.<sup>[3]</sup> Various techniques and material were used by surgeons over years to control appearance of free PR during index operation.<sup>[4]</sup> Traditionally, untreated autologous pericardium was utilized with not very encouraging early and midterm results.<sup>[5]</sup> They were considered to disappear by resorption and retraction and soon were replaced by glutaraldehyde treated autologous pericardium at pulmonary

This is an open access journal, and articles are distributed under the terms of the Creative Commons Attribution-NonCommercial-ShareAlike 4.0 License, which allows others to remix, tweak, and build upon the work non-commercially, as long as appropriate credit is given and the new creations are licensed under the identical terms.

**For reprints contact:** WKHLRPMedknow\_reprints@wolterskluwer.com

**How to cite this article:** Pande S, Arya A, Agarwal SK, Tewari P, Kapoor A, Soni N, *et al.* Long-term performance of untreated fresh autologous pericardium as a valve substitute in pulmonary position. *Ann Card Anaesth* 2022;25:164-70.

Access this article online	
Quick Response Code:	Website: www.annals.in
	DOI: 10.4103/aca.aca_22_21

position as monocusp valve for right ventricular outflow tract (RVOT) reconstruction with good midterm results.<sup>[6]</sup> Some groups started using poly tetra fluoro ethylene (PTFE) membrane for reconstruction of pulmonary valve and have shown acceptable midterm results.<sup>[7]</sup> Apart from techniques of creating a monocusp, bicuspid or a tricuspid valve at pulmonary position some groups perform aggressive debulking and release of native pulmonary valve and annulus with acceptance of a small z value to contain the PR after RVOT reconstruction.<sup>[8]</sup> In addition to this knowledge, we have been using untreated fresh autologous pericardium for reconstruction of pulmonary valve in subset of TOF requiring trans annular patch for a decade now. We analyze the hemodynamic and physiologic performance of untreated pericardium used as a valve in long-term.

## MATERIAL AND METHODS

This is a cross sectional study performed at a single center. Between January 2007 and December 2012, 92 patients of tetralogy of Fallot were operated in the unit. Of these 72 patients required trans annular patch for complete intracardiac repair of the TOF. All the patients requiring a TAP, received some kind of procedure for creation of a competent pulmonary valve (valve substitute). The procedure to achieve a competent valve was performed at newly created pulmonary annulus after the use of trans annular patch. It was either a monocusp (n = 61) created on the TAP anteriorly or a tricuspid pulmonary valve (n = 11) after complete excision of the native pulmonary valve.<sup>[9,10]</sup> The material used for creating a competent pulmonary valve in both these techniques was untreated fresh autologous pericardium. This study was approved by the research and ethics committee of the institute. Funds were granted to include up to 20% of cases for this study. The inclusion criteria were, patient with more than 3 years of follow-up, in normal sinus rhythm and absence of allergy to iodine-based dye. Patients who came for follow-up were offered the chance to participate in the study and it was closed when desired numbers were reached. Those patients were excluded who did not consent and presented with rhythm abnormalities. Finally, 19 patients participated in the study. Fifteen patients required a transannular patch during operation and of these 11 received a monocusp valve and 4 received a tricuspid valve at pulmonary position. Four patients did not require a TAP and thus their pulmonary valve was not violated. The patients were grouped into 2 categories. Group 1 (n = 4), included patients with normal pulmonary valve and no TAP while group 2 (n = 15) has patients with TAP and either a monocusp or a tricuspid valve. The clinical data was collected through an interview and operative details were accessed through hospital information system. The patients

were evaluated for right ventricular function, degree of PR and gradient across the right ventricular outflow tract using Philips HD echocardiography machine and a 3.2-MHz transducer (Philips Medical Systems, Andover, MA).

### Assessment of right ventricular function

It was done using Myocardial Performance Index (MPI), Tricuspid Annular Plane Systolic Excursion (TAPSE). A value of MPI of 0.40 and TAPSE of <14 mm was considered as severe right ventricular dysfunction.<sup>[11,12]</sup>

### Assessment of Pulmonary regurgitation and gradient across RVOT

PR was assessed by pulmonary end diastolic velocity and labelled as severe when it reached zero. If not severe, the PR was labelled as hemodynamically significant if its duration was less than 70% of diastolic duration.<sup>[13]</sup> Assessment of gradient across RVOT was done on continuous wave doppler by assessment of velocity across it.

### Assessment for dimensions of the FAP used in creation of competent pulmonary valve

A contrast cardiac PET CT scan study was performed in all the patients to study the anatomy of the untreated autologous pericardium (UAP) at the follow-up. All the patients were kept fasting overnight and were injected 18-Fluoro Deoxy Glucose 45 minutes before commencement of the study. A 64 slice CT scanner was used for the purpose (Biograph by Siemens, Munich, Germany). A prospective electrocardiogram gated scan was performed with 0.9 mm thickness with controlled heart rate of <70 beats/minute. The trigger was kept in right ventricle and area of interest for study was right ventricle, RVOT and pulmonary valve with main pulmonary artery. The anatomy was evaluated on CT images. A non-ionic contrast (Visipaque) was used for this study. Since majority of patients (n = 11) has a monocusp of UAP, the anterior leaflet (cusp) of pulmonary valve was evaluated in all the patients to have uniformity in comparison. The assessment was done for height (coaptation surface), width (circumference of the cusp along the annulus) and thickness of the anterior cusp of neo pulmonary valve.

### Assessment of uptake of 18 Fluoro Deoxy Glucose (18-FDG) by valves

Following completion of the CT scan protocol, the patients were scanned for positron emission tomography (PET) in the same position for next 45 minutes. The overlapping of the two images was done to create the data for assessment of 18-FDG uptake by the native aortic valve, native pulmonary valve (in 11 cases of monocusp of UAP where the native pulmonary valves were retained during total



correction, these are located posteriorly on the pulmonary annulus). The standard uptake value (SUV) of 8 mm circle was calculated at the valve leaflet near their coapting edges. This was done to remove any overlap that may have occurred due to uptake by the wall of great arteries. The calculation for UAP was done in the anterior leaflet of the neo pulmonary valve. The target blood ratio (TBR, was calculated as a ratio of SUV of the target tissue and the SUV of the blood pool) from attenuation corrected images was achieved and is used in statistical analysis as uptake of glucose by the valve leaflet tissue.

### Statistics

The data is presented in median (minimum – maximum). The comparison between different style of neo pulmonary valve is done using non-parametric test, Mann Whitney U test. Pearson correlation is calculated between different variables. SPSS version 17 for windows is used for statistical analysis.

### RESULTS

The median age of the patients is 14 years (9 – 37) and there are 16 males and 3 females in this study. The complete data of 19 patients for echocardiography is presented in Table 1, for measurements of monocusp, based on CT scan, in Table 2 and glucose uptake in Table 3. While comparing group 1 and 2, there was no difference in the age of the patients (13 years (9 – 17) vs 16 years (10 – 37),  $P = 0.73$ ) or their distribution based on sex (3 males and 1 female vs 13 males and 2 females,  $P = 0.26$ ). The right ventricular function was similar in two groups, TAPSE in mm of 16.9 (13.9 – 19.4) in group 1 vs 19 (10.6 – 22.8) in group 2  $P = 0.53$  and MPI of 0.28 (0.05 – 0.56) in

group 1 vs 0.09 (0.01 – 0.41) in group 2  $P = 0.50$ . The comparison of the function of preserved native pulmonary in group 1 and the reconstructed pulmonary valve in group 2 is presented in Table 4. The uptake of glucose by monocusp, native pulmonary valve leaflet and aortic valve leaflet is displayed in Figure 1. The measurements and appearance of monocusp in CT scan obtained image is presented in Figure 2. There was no evidence of calcium deposition in any scan. Figure 3, displays the PET CT attenuation corrected image of the same patient. The TBR of glucose uptake was 0.945 (0.17 – 3.35) for monocusp, 0.805 (0.14 – 0.328) for native pulmonary leaflet and 1.05 (0.21 – 3.71) for aortic valve leaflet. There is a strong correlation between TBR of monocusp and the period of follow-up ( $r = 0.601$ ,  $P = 0.01$ ). There is also a strong positive correlation between the TBR of monocusp and aortic valve leaflet ( $r = 0.956$ ,  $P = 0.001$ ) and monocusp and native pulmonary valve leaflet (0.958,  $P = 0.001$ ). There was change in the size of pericardium at the follow-up. In all 15 patients in which UAP was used to create a pulmonary valve there was change in the size of the pericardium used to create anterior cusp. The change is shrinkage in height by 35.5% (70 – 1.0) and width by 7% (-44% - +104%) from its initial dimensions. When the size of the pericardium measured at follow-up is compared to its size at the time of implantation, there is a significant shrinkage in height (25 mm (12 – 30) at the time of implantation vs 13.5 mm (8.9 – 19.4) at the time of follow-up,  $P = 0.007$ ). While the length of the pericardium slightly decreased though not significantly (25 mm (4.71 – 30) vs 23.4 (4.9 – 40.9),  $P = 0.91$ ). The change in size of the pericardium used for monocusp was relatively less in patients younger than 15 years Figure 4.

**Table 1: Echocardiography derived right ventricle function parameters**

Patient	Type of PV	MPI	TAPSE in mm	Mean PV gradient in mmHg	PR in grade	PR end diastolic velocity in cm/sec	EOA in cm <sup>2</sup> /m <sup>2</sup>
1	Native normal PV	0.48	19.40	7.00	1	38.80	1.37
2		0.56	13.90	10.00	1	38.80	1.60
3		0.05	15.00	8.00	4	96.40	1.83
4		0.08	18.90	9.00	1	45.50	1.85
5	Monocusp of UAP Pericardium at PV annulus	0.19	22.70	11.00	4	42.40	2.45
6		0.07	14.70	10.00	1	68.80	1.25
7		0.08	18.70	5.00	2	160.00	1.70
8		0.07	16.00	13.00	2	10.90	1.22
9		0.16	20.90	30.00	2	69.20	2.45
10		0.07	19.00	17.00	1	38.00	1.25
11		0.08	16.00	16.00	3	51.60	3.09
12		0.10	22.70	22.00	2	95.00	2.09
13		0.24	20.00	23.00	1	77.40	1.95
14	Tricuspid neo PV created from UAP	0.31	11.70	8.00	4	65.00	6.53
15		0.10	22.80	12.00	4	89.60	1.44
16		0.01	10.60	10.00	4	50.20	1.79
17		0.19	19.00	27.00	2	65.40	1.54
18		0.41	21.90	19.00	4	102.00	1.07
19		0.06	13.00	13.00	2	42.10	0.835

MPI: Myocardial Performance Index, PV: Pulmonary Valve, PR: Pulmonary Regurgitation, UAP: Untreated autologous pericardium



**Table 2: Anatomical measurements of UAP of anterior leaflet of reconstructed pulmonary valve on CT scan**

Patient	Type of PV	Age	Width of UAP created anterior cusp of PV at operation in mm	Height of UAP created anterior cusp of PV at operation in mm	Width of UAP Anterior cusp at follow-up in mm	Height of UAP Anterior cusp in follow-up in mm	Thickness of UAP Anterior cusp at follow-up in mm
1	Native normal PV	12			12.00	10.40	1.40
2		17			14.10	11.10	1.60
3		14			15.50	10.90	1.25
4		09			14.40	10.30	1.50
5	Monocusp of UAP at PV annulus	17	15.71	25.00	25.60	12.90	1.70
6		10	20.00	22.00	19.60	17.40	1.30
7		23	30.00	30.00	27.90	19.00	1.70
8		12	30.00	30.00	15.20	18.00	1.70
9		24	25.00	30.00	29.20	8.90	2.50
10		21	25.00	25.00	28.40	15.40	3.00
11		16	20.00	20.00	39.50	13.20	2.00
12		14	30.00	30.00	24.00	22.00	1.50
13		14	25.00	25.00	18.00	16.00	1.10
14		18	25.00	21.00	22.50	20.00	2.60
15	Tricuspid neo PV created from UAP	12	4.71	12.00	4.90	9.70	1.60
16		10	20.00	21.00	29.00	13.50	1.60
17		10	20.00	15.00	40.90	15.70	2.10
18		37	25.00	30.00	13.90	19.40	1.60
19		31	30.00	30.00	22.80	20.00	2.60

PV: Pulmonary valve, UAP: Untreated autologous pericardium

**Table 3: Measurements of uptake of glucose as TBR in PET scan**

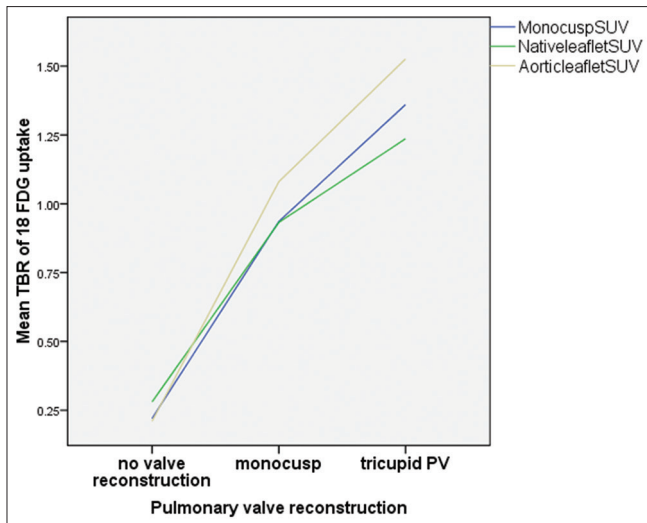
Patient	Type of PV	Follow-up period in years	TBR of UAP Anterior cusp of PV	TBR of native aortic valve	TBR of native pulmonary valve
1	Native normal PV	3	0.24	0.20	0.30
2		5	0.26	0.21	0.42
3		3	0.18	0.21	0.14
4		4	0.20	0.24	0.18
5	Monocusp of UAP at PV annulus	4	0.17	0.43	0.24
6		4	0.90	0.75	0.66
7		3	1.25	1.45	1.25
8		3	0.54	0.66	0.73
9		7	1.04	1.27	1.22
10		7	0.94	1.33	1.33
11		4	0.95	1.27	0.76
12		9	1.24	1.43	1.13
13		8	1.47	1.00	0.91
14		4	0.82	0.88	0.82
15	Tricuspid neo PV created from UAP	3	0.82	0.60	0.66
16		6	1.04	1.10	
17		9	3.35	3.71	
18		3	0.37	0.39	
19		3	1.22	1.83	

PET: Positron emission tomography, PV: Pulmonary valve, TBR: Target blood ration of standard uptake value, UAP: Untreated autologous pericardium

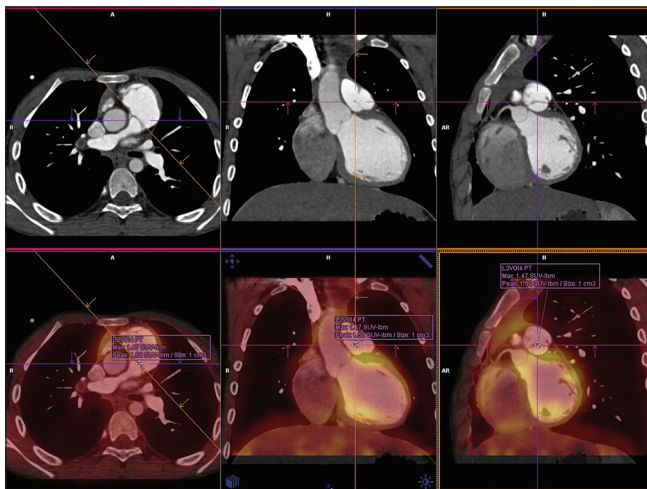
## DISCUSSION

The need for inclusion of a competent pulmonary valve following repair of tetralogy of fallot is to prevent right ventricular failure arising out of the effect of long-standing pulmonary regurgitation.<sup>[14]</sup> However, a dream of competent pulmonary valve after a transannular patch, though utopian, has been regarded as a fool's errand.<sup>[15]</sup> In our study of fairly long follow-up, the function of right ventricle was preserved in all the patients as reported by other studies.<sup>[16]</sup> This has also been documented in 5-year follow-up of repaired tetralogy of fallot in our experience.<sup>[17]</sup> A long-term exposure of pulmonary regurgitation is physiologically

untenable for right ventricle to maintain its function and eventually it fails.<sup>[18]</sup> Hence authors believe any attempt to mitigate the development of pulmonary regurgitation will help in delaying the development of right ventricle dysfunction. Pulmonary regurgitation was moderate in most of our patients and effective orifice area indexed was also in normal range, hence the construction of neo valve at pulmonary annulus had prevented ballooning of the transannular patch and free pulmonary regurgitation. The method for inserting a monocusp in right ventricular outflow as patch rather than at annulus has failed to be functional at follow-up.<sup>[19]</sup> It is also documented in our study, that this neo pulmonary valve is non-obstructive at



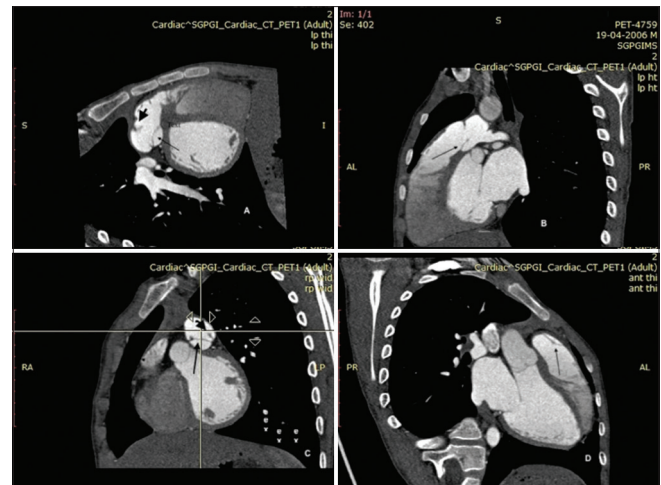
**Figure 1:** Displays correlation between TBR (Target blood ratio of standard uptake value of 18 fluoro deoxy glucose) between monocusp of untreated autologous pericardium, aortic valve leaflet and native pulmonary valve



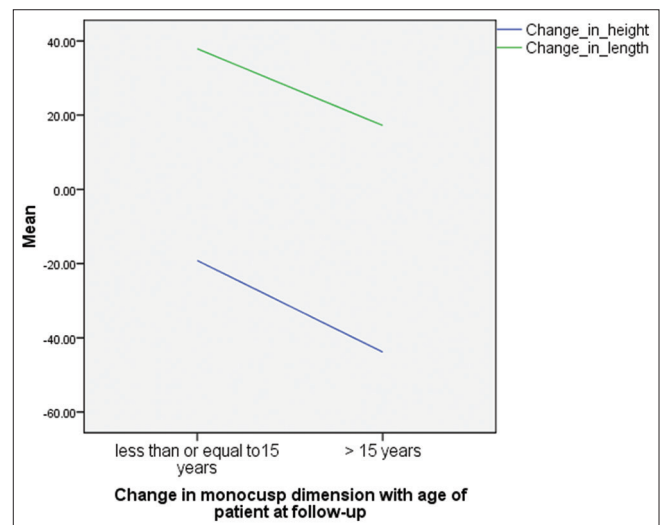
**Figure 3:** Fused positron emission tomography and CT images of the same patient as in Figure 2

long term follow-up as evidenced by an acceptable mean gradient across it of <30 mm Hg.

In our study, we used autologous untreated pericardium for preparation of a competent pulmonary valve either as monocusp or a tricusp valve. It is observed in follow-up with CT scan, that the autologous pericardium has no deposition of calcium in all our patients. However, it has revealed thickness and distortion. This change can be explained by excessive fibroblastic activity. Grabenwoger *et al.* experimented with autologous and heterologous pericardial valve, on explanation they found the autologous tissue to be free of calcification but heterologous valve failed because of calcification of the tissue. They had treated the autologous pericardium with glutaraldehyde



**Figure 2:** CT scan images in different views showing monocusp leaflet of neo pulmonary valve (thin arrow) and native pulmonary valve leaflet (thick arrow)



**Figure 4:** Difference in shrinkage of monocusp from its initial dimensions in patients with age less or more than 15 years

**Table 4: Function of neo pulmonary valve in follow-up Echocardiography**

Variable	Group I n=4	Group II n=15	P
Peak Gradient in mmHg	15.5 (14 - 20)	35 (10 - 62)	0.02
Mean gradient in mm Hg	8.5 (7 - 10)	14.5 (5 - 30)	0.02
RVSP in mm Hg	41 (39 - 43)	41 (36 - 53)	1.0
TR grade	1 (0 - 2)	1 (1 - 4)	0.66
PAEDV	42.4 (38.8 - 96.4)	68.8 (10.9 - 160)	0.70
EOAI cm/m <sup>2</sup>	1.46 (1.13 - 4.86)	2.11 (0.99 - 4.17)	0.50

RVSP: Right Ventricular Systolic Pressure, TR: Tricuspid Regurgitation, PAEDV: Pulmonary artery End Diastolic Velocity, EOAI: Effective Orifice Area Index

hence the growth of collagen was missing in their study.<sup>[20]</sup> Dham *et al.* demonstrated their experience with autologous pericardial valve (ATCV).<sup>[21]</sup> They did histopathological study in two failure patients. The method of failure was shrinkage and thickening in one case and collagen

degeneration in other. They short tanned the pericardium with glutaraldehyde.<sup>[22]</sup> We have observed shrinkage in height of the cusp in our patients. This has been the reported problem with the use of untreated pericardium.<sup>[23]</sup> Though in our series we have noted growth in width of the monocusp, more significantly in patients who were below 15 years. This observation in our study may be because of the inherent property of the untreated pericardium to increase in length on stretch with the capability of regain its normal size after few hours.<sup>[24]</sup> In our experience the pericardium used as monocusp, increased in length (the aspect of monocusp that was stitched along the neo pulmonary annulus) while it shrinks in height (the coapting height of monocusp). Haluk *et al.* has also reported increase in the size of untreated pericardium when they used it as a patch on aorta in experimental animal.<sup>[25]</sup> Similarly, Quinn *et al.* has reported successful use of untreated pericardium for mitral valve repair. They report that after 10 years of follow-up, the pericardium thus used, shows no calcification, aneurysmal dilation or stiffness.<sup>[26]</sup> We also observed similar characteristics in monocusp made from untreated autologous pericardium.

PET scan in our study reveals uptake of glucose by the monocusp. This uptake of glucose is similar to the uptake of glucose by the aortic valve and native pulmonary valve leaflet of the same patient. Marincheva-Savcheva *et al.* reported increased uptake of glucose by the stenosed aortic valve. They have discussed the uptake in aortic stenosis as a part of inflammation. The mean valve for uptake in mild aortic stenosis was 1.35 which is higher than that observed in our study.<sup>[27]</sup> It is also noteworthy that in patients who did not require a monocusp and thus had normal pulmonary valve had lower uptake value of glucose. However, in monocusp category the uptake of glucose was increased in aortic as well as monocusp, though in approximately equal proportions. It was observed after a valve implantation that there was targeting of the area by host reaction.<sup>[28]</sup> This is later followed by increased collagenization and re endothelization.<sup>[28]</sup> Mathieu *et al.* has reported uptake around the sewing ring of the bio prosthetic valve even at 1 year and has hypothesized that this remodeling process (increased fibrous reaction) may be the reason for increased uptake.<sup>[29]</sup> The uptake in cases of infection and inflammation is much higher in numbers than observed in our study. Kieder *et al.* has reported increased uptake of glucose in case of implantation of vascular prosthesis while in cases of native vein graft these values were significantly reduced.<sup>[30]</sup> In our cases the uptake of glucose may be similarly explained by the remodeling process of the autologous pericardium. The free edge of the monocusp possibly got retracted due to

collagenization. The monocusp in our study has thus shown all the characteristics of a living tissue, however there was retraction in its free edge which is a concern. The use of untreated pericardium as a material to create a valve will in future be decided by the fact if its remodeling process can be altered favorably.

This study has few limitations and future efforts must be directed to addressing them. All the patients treated could not be enrolled in this study for follow-up. This created a bias in selection of patients. We have compared two techniques for creating a competent pulmonary valve, the monocusp and a tricuspid valve. Both of these would create different amount of stress on the FAP valve cusp, thus altering the amount of injury and hence healing response.

## CONCLUSION

This study establishes the presence of a supple, non-calcified, monocusp leaflet which is able to reduce the pulmonary regurgitation and maintain normal functioning of right ventricle at long term. Though this monocusp has demonstrated thickening with retraction in its free (coopting) edge, it has also demonstrated its capability to increase in length so that the neo pulmonary annulus can grow to meet the demand of growing child. The standardization of design of the neo pulmonary valve and modulation of the remodeling of autologous pericardium will be required for the success of such valves.

## Acknowledgement

This article is product of the intramural research grant from the institute

## Financial support and sponsorship

Nil.

## Conflicts of interest

There are no conflicts of interest.

## REFERENCES

1. Gatzoulis MA, Balaji S, Webber SA, Siu SC, Hokanson JS, Poile C, *et al.* Risk factors for arrhythmia and sudden cardiac death late after repair of tetralogy of Fallot: A multicenter study. *Lancet* 2000;356:975-81.
2. Peng EW, Lilley S, Knight B, Siu SC, Hokanson JS, Poile C, *et al.* Synergistic interaction between right ventricular mechanical dyssynchrony and pulmonary regurgitation determines early outcome following tetralogy of Fallot repair. *Eur J Cardiothorac Surg* 2009;36:694-702.
3. Sasson I, Hourii S, Raucher S A, Cohen I, Lenczner O, Bove EL, *et al.* Right ventricular outflow tract strategies for repair of tetralogy of Fallot: Effect of monocusp valve reconstruction. *Eur J Cardiothorac Surg* 2013;43:743-51.
4. Vricella LA, Kanani M, Cook AC, Cameron DE, Tsang VT. Problems with the right ventricular outflow tract: A review of



- morphologic features and current therapeutic options. *Cardiol Young* 2004;14:533-49.
5. Dahl M, Prüfer D, Mayer E, Groh E, Choi YH, Oelert H. Early failure of an autologous pericardium aortic heart valve (ATCV) prosthesis. *J Heart Valve Dis* 1998;7:30-3.
6. Sung SC, Kim S, Woo JS, Lee YS. Pulmonic valve annular enlargement with valve repair in tetralogy of Fallot. *Ann Thorac Surg* 2003;75:303-5.
7. Wankhade PR, Aggarwal N, Joshi RK, Agarwal M, Joshi R, Mehta A, *et al*. Short-term clinical and echocardiographic outcomes after use of polytetrafluoroethylene bicuspid pulmonary valve during the repair of tetralogy of Fallot. *Ann Pediatr Cardiol* 2019;12:25-31.
8. Bové T, François K, De Kerckhove KV, Panzer J, De Groote K, De Wolf D, *et al*. Assessment of a right-ventricular infundibulum-sparing approach in transatrial-transpulmonary repair of tetralogy of Fallot. *Eur J Cardiothorac Surg* 2012;41:126-33.
9. Pande S, Agarwal SK, Majumdar G, Chandra B, Tewari P, Kumar S. Pericardial monocusp for pulmonary valve reconstruction: A new technique. *Asian Cardiovasc Thorac Ann* 2010;18:279-84.
10. Pande S, Agarwal SK, Majumdar G, Narwale M, Shukla R, Arora M. Reconstruction of Trileaflet Pulmonary Valve Using Autologous Pericardium. *Heart Lung Circ* 2011;20:325-8.
11. Rudski LG, Lai WW, Afilalo J, Hua L, Handschumacher MD, Chandrasekaran K, *et al*. Guidelines for the echocardiographic assessment of the right heart in adults: A report from the American Society of Echocardiography. *J Am Soc Echocardiogr* 2010;23:685-713.
12. Frea S, Pidello S, Bovolo V, Iacovino C, Franco E, Pinneri F, *et al*. Prognostic incremental role of right ventricular function in acute decompensation of advanced chronic heart failure. *Eur J Heart Fail* 2016;18:564-72.
13. Li W, Davlouros PA, Kilner PJ, Pennell DJ, Gibson D, Henein MY, *et al*. Doppler-echocardiographic assessment of pulmonary regurgitation in adults with repaired tetralogy of Fallot: Comparison with cardiovascular magnetic resonance imaging. *Am Heart J* 2004;147:165-72.
14. Greutmann M, Tobler D, Biaggi P, Mah ML, Crean A, Oechslin EN, *et al*. Echocardiography for assessment of right ventricular volumes revisited: A cardiac magnetic resonance comparison study in adults with repaired tetralogy of Fallot. *J Am Soc Echocardiogr* 2010;23:905-11.
15. Bacha EA. Functional pulmonary valve after tetralogy of Fallot repair: A fool's errand? *J Thorac Cardiovasc Surg* 2018;155:1161-2.
16. Gatzoulis MA, Clark AL, Cullen S, Newman CG, Redington AN. Right ventricular diastolic function 15 to 35 years after repair of tetralogy of Fallot. Restrictive physiology predicts superior exercise performance. *Circulation* 1995;91:1775-81.
17. Pande S, Sharma JK, Siddhartha CR, Bansal A, Agarwal SK, Tewari P, *et al*. Fresh autologous pericardium to reconstruct the pulmonary valve at the annulus when tetralogy of fallot requires a transannular patch at midterm. *Tex Heart Inst J* 2016;43:207-13.
18. Leeuwenburgh BP, Helbing WA, Steendijk P, Schoof PH, Baan J. Biventricular systolic function in young lambs subject to chronic systemic right ventricular pressure overload. *Am J Physiol Heart Circ Physiol* 2001;281:H2697-704.
19. Gundry SR, Razzouk AJ, Boskind JF, Bansal R, Bailey LL. Fate of the pericardial monocusp pulmonary valve for right ventricular outflow tract reconstruction: Early function, late failure without obstruction. *J Thorac Cardiovasc Surg* 1994;107:908-13.
20. Grabenwöger M, Fitzal F, Gross C, Hutschala D, Böck P, Brucke P, *et al*. Different modes of degeneration in autologous and heterologous heart valve prostheses. *J Heart Valve Dis* 2000;9:104-9.
21. Fabiani I, N, Dreyfus GO, Marchand M, Jourdan J, Anpard M, Latre-monille C. The autologous tissue cardiac valve: A new paradigm for heart valve replacement. *Ann Thorac Surg* 1995;60:189-94.
22. Dahm M, Prufer D, Dohmen G, Mayer E, Groh E, Choi Y-H, *et al*. Pathophysiology of early failure of autologous aortic heart valves (ATCV). *Thorac Cardiovasc Surg* 1998;46:344-7.
23. Bjork VO, Hultquist G. Teflon and pericardial aortic valve prostheses. *J Thorac Cardiovasc* 1964;47:693-701.
24. Trowbridge EA, Crofts CE. The standardisation of gauge length: Its influence on the relative extensibility of natural and chemically modified pericardium. *J Biomech* 1986;19:1023-33.
25. Haluk RS, Richenbacher WE, Myers JL, Miller CA, Wise RK, Waldhausen JA. Pericardium as a thoracic aortic patch: Glutaraldehyde-fixed and fresh autologous pericardium. *J Surg Res* 1990;48:611-4.
26. Quinn RW, Wang L, Foster N, Pasrija C, Ghoreishi M, Dawood M, *et al*. Long term performance of fresh autologous pericardium for mitral valve leaflet repair. *Ann Thorac Surg* 2020;109:36-41.
27. Marincheva- Savcheva G, Subramanian S, Qadir S, Pasrija C, Ghoreishi M, Dawood M, *et al*. Imaging of the aortic valve using fluorodeoxyglucose positron emission tomography increased valvular fluorodeoxyglucose uptake in aortic stenosis. *JACC* 2011;57:2507-15.
28. Siddiqui RF, Abraham JR, Butany J. Bioprosthetic heart valves: Modes of failure. *Histopathology* 2009;55:135-44.
29. Mathieu C, Mikail N, Benali K, Iung B, Duval X, Nataf P, *et al*. Characterization of <sup>18</sup>F-fluorodeoxyglucose uptake pattern in noninfected prosthetic heart valves. *Circ Cardiovasc Imaging* 2017;10:e005585.
30. Keidar Z, Pirmisashvili N, Leiderman M, Nitecki S, Israel O. 18F-FDG uptake in noninfected prosthetic vascular grafts: Incidence, patterns, and changes over time. *J Nucl Med*. 2014;55:392-5.